International Journal of Dermatology

Review

Management of digital mucous cysts: a systematic review and treatment algorithm

Samer Jabbour[1], MD, Elio Kechichian[2], MD, Roger Haber[2], MD, Roland Tomb[2], PHD, and Marwan Nasr[1], MD

[1]Department of Plastic and Reconstructive Surgery, Faculty of Medicine, Saint Joseph University, Hotel Dieu de France Hospital, Beirut, Lebanon, and [2]Department of Dermatology, Faculty of Medicine, Saint Joseph University, Hotel Dieu de France Hospital, Beirut, Lebanon

Correspondence
Samer Jabbour, MD
Department of Plastic and Reconstructive Surgery
Faculty of Medicine
Saint Joseph University
Hotel Dieu de France Hospital
Alfred Naccache Blvd, Achrafieh
Beirut 1100 2160
Lebanon
E-mail: samermed@gmail.com

The first two authors contributed equally to this review and are coauthors.

Funding: None.

Conflicts of interest: None.

doi: 10.1111/ijd.13583

Abstract

Digital mucous cysts (DMC) are benign, highly recurrent lesions of the digits. To date, there is still no treatment agreement on the treatment of DMC. Herein, we review available data on treatment modalities, including both surgical and nonsurgical techniques, and to provide a practical algorithm for the management of DMC. A systematic review was conducted using MEDLINE, EMBASE, and Cochrane databases. Articles studying the management of DMC were included in this review. A total of 40 articles were included in the review. The five most frequently used treatments for DMC were surgery ($n = 849$), expression of cyst content ($n = 132$), sclerotherapy ($n = 119$), corticosteroid injection ($n = 108$), and cryotherapy ($n = 103$). Surgery yielded the highest cure rate among all treatment modalities (95%) compared to sclerotherapy (77%), cryotherapy (72%), corticosteroid injection (61%), and expression of cyst content (39%) ($P < 0.001$). Surgery should be considered as the first-line treatment for DMC. Second-line treatments include sclerotherapy and cryotherapy. Third-line treatments include corticosteroid injections, expression of cyst content, and less-studied modalities. Surgery showed the highest cure rates. Future adequately designed randomized controlled trials are warranted to compare different treatment modalities.

Introduction

Digital mucous cysts (DMC), also known as myxoid cysts, synovial cysts, mucous cysts, and myxomatous cutaneous cysts, were first described in 1883 by Hyde as synovial lesions of the skin.[1] These benign myxoid cysts typically involve the lateral or dorsal surfaces of the distal interphalangeal joint or the proximal nail fold on the fingers and less commonly on the toes[2] and present as a 3–10 mm translucent, solitary smooth nodule.[1,3,4] Subungual mucous cysts and multiple mucous cysts are rare occurrences.[5] Mucous cysts tend to affect individuals between 50 and 70 years old,[6] women more than men (around 47% of patients being males).[7–9] The exact mechanism of DMC formation is still unknown. The DMCs probably result from degenerative changes in the fibrous capsule of the joint or synovial tissue,[10] especially that a communication between the cyst and adjacent joint space has been demonstrated.[1] The development of osteophytes and an increase in synovial fluid associated with osteoarthritis (OA) are contributing factors to the formation of DMCs since the prevalence of mucous cysts in OA ranges from 64[11] to 93%.[7] Mucous cysts are considered pseudocysts since they do not contain a true epithelial lining and cyst wall. They are formed by a herniation of the joint capsule, and the lining of the DMC is in fact formed by fibroblasts surrounded by compressed connective tissue.[4,12,13] The content of DMC is debatable. Histology usually reveals a pseudocyst cavity within a fibrous capsule containing a myxomatous stroma with scattered fibroblasts.[14] DMCs are often asymptomatic but may occasionally be associated with decreased range of motion, pain, tenderness, nail deformities, and periodic spontaneous discharge.[15] Despite few reports of spontaneous regression, treatment is usually needed.[8] Nonsurgical management such as puncturing, sclerotherapy, steroid injection, hyaluronidase injection, cryosurgery, and carbon-dioxide vaporization have been considered.[12,16–19] Surgical treatment has also been reported with varying cure rates and includes excision of the cyst, with or without osteophyte, followed by overlying skin removal and skin graft or flap coverage.[7,10,20–23] However, to date, there is still no

© 2017 The International Society of Dermatology

Table 1 Characteristics of included surgical studies

Study (year)	Study type (GRADE)[a]	Lesions (*n*)	Procedure description
Constant *et al.* (1969)[25]	R – (4)	12	Cyst excision via simple incision with primary skin closure
Abe *et al.* (2004)[26]	R – (2b)	84	
Crawford *et al.* (1990)[10]	P – (2b)	25	
Lawrence (2005)[8]	P – (2b)	32	Elevation of a proximally based flap covering the cyst followed by removal of the cyst
Arenas-Prat (2015)[27]	R – (4)	14	
De Berker and Lawrence (2001)[19]	P – (2b)	54	Ligation of cyst pedicule
Kanaya *et al.* (2014)[28]	P – (2b)	19	Resection of the dorsal half of the DIPJ capsule
Baazil *et al.* (2015)[34]	R – (2b)	23	Cyst and osteophyte excision with primary skin closure
Hoshino *et al.* (2010)[30]	R – (4)	6	
Rizzo and Beckenbaugh (2003)[33]	R – (2b)	54	
Brown *et al.* (1991)[29]	R – (2b)	22	
Kasdan *et al.* (1994)[24]	R – (2b)	113	
Constant *et al.* (1969)[25]	R – (4)	30	Cyst and skin excision with FTSG
Crawford *et al.* (1990)[10]	P – (2b)	12	Excision of the cyst and an ellipse of skin followed by rotation-advancement of a skin flap
Imran *et al.* (2003)[22]	R – (4)	6	Excision of the cyst and an ellipse of skin followed by a rhomboid flap
Calder *et al.* (2003)[55]	R – (2b)	15	Excision of an ellipse of skin, the cyst, the joint capsule, and osteophytes followed by a primary closure
Jamnadas-Khoda *et al.* (2009)[35]	R – (2b)	51	Cyst, skin, and osteophyte excision with FTSG
Baazil *et al.* (2015)[34]	R – (2b)	45	
Hojo *et al.* (2016)[36]	P – (2b)	37	Excision of the cyst along with the skin, joint debridement, and coverage with a local flap
Jager *et al.* (2012)[37]	R – (4)	9	
Johnson *et al.* (2014)[38]	R – (2b)	69	
Young and Campbell (1999)[20]	R – (4)	6	
Maccollum (1975)[39]	R – (4)	22	
Blanc *et al.* (2004)[40]	R – (2b)	27	
Lee *et al.* (2014)[32]	R – (2b)	42	Osteophyte excision without cyst excision
Gingrass *et al.* (1995)[31]	P – (2b)	20	

R, retrospective; P, prospective; DIPJ, distal interphalangeal joint; FTSG, full thickness skin graft.
[a]Centre for Evidence-Based Medicine Oxford (1a-5).

Table 2 Characteristics of included nonsurgical studies

Study (year)	Study type (GRADE)[a]	Lesions (*n*)	Procedure description
Cordoba *et al.* (2008)[41]	R – (4)	6	Injection of 0.5–1 ml of 2% polidocanol. Repeated at 4-week intervals
Esson and Holme (2016)[42]	P – (2b)	63	Injection of 3% polidocanol (0.02–0.5 ml). Repeated at 6-week intervals
Park *et al.* (2014)[43]	R – (2b)	20	Injection of 0.2–0.5 ml of 1–3% sodium tetradecyl sulfate. Repeated at 4-week intervals
Sung and Roh (2014)[44]	R – (2b)	12	Injection of 0.2–0.3 ml of 0.5% sodium tetradecyl sulfate. Repeated at 2-week intervals
Tanaka *et al.* (2009)[45]	R – (2b)	18	Injection of 0.2–0.3 ml of OK432 (lyophilized strep pyogenis)
Böhler-Sommeregger and Kutschera-Hienert (1988)[46]	R – (2b)	17	1 or 2 cycles of liquid nitrogen using an intermittent open spray technique
Dawber *et al.* (1983)[47]	R – (2b)	14	Two freeze-thaw cycles
Kuflik (1992)[48]	R – (2b)	57	Application of liquid nitrogen with a cryoprobe or an open spray
Minami *et al.* (2007)[49]	R – (4)	15	3–5 cycles of liquid nitrogen. Repeated every 2 weeks
Rizzo and Beckenbaugh (2003)[33]	R – (2b)	80	Injection of a 3 : 1 dilution of 1% lidocaine without epinephrine and betamethasone
Dodge *et al.* (1984)[50]	R – (2b)	28	ILCSI
Epstein (1979)[51]	R – (4)	40	Multiple percutaneous punctures with a needle
Abe *et al.* (2004)[26]	R – (2b)	55	
Esteban *et al.* (1986)[52]	R – (4)	6	Needle aspiration
Rollins *et al.* (2013)[53]	R – (2b)	31	
Huerter *et al.* (1987)[17]	R – (4)	10	CO2 laser vaporization, 5–10 watts
Karrer *et al.* (1999)[54]	R – (4)	6	
Kemmett and Colver (1994)[18]	R – (4)	14	Infrared coagulation
Lonsdale-Eccles and Langtry (2005)[12]	R – (4)	23	

R, retrospective; P, prospective; ILCSI, intralesional corticosteroid injection.
[a]Centre for Evidence-Based Medicine Oxford (1a-5).

 © 2017 *The International Society of Dermatology*

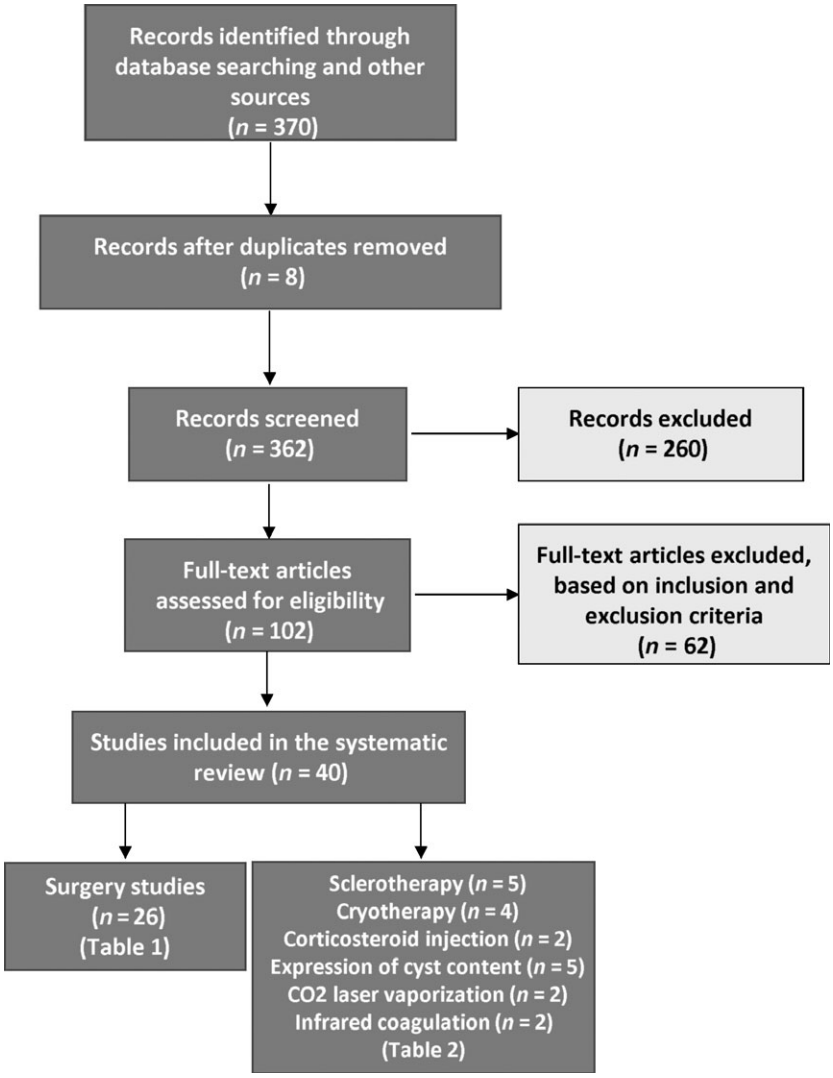

Figure 1 Stepwise approach used to select the articles included in the review

agreement on the best treatment of DMC. The purpose of this article is to review all available data on available treatment techniques, surgical and nonsurgical, and to provide a practical algorithm for the management of DMC.

Materials and methods

Search description

On March 29, 2016, we conducted a systematic review of published articles in MEDLINE, EMBASE, and Cochrane databases. The search was done with no restrictions using specific terms for DMC ("ganglionic cyst" or "ganglion cyst" or "myxoid cyst" or "mucous cyst" or "synovial cyst") combined with keywords to narrow the search to cysts located on fingers or toes ("digit" or "digits" or "digital" or "thumb" or "index" or "finger" or "toe" or "toes"). All studies related to the treatment of DMC published in English or French until the search date were included in the systematic review. Only the studies about DMC treatment were selected. Cure was defined as complete healing of the cyst with no recurrence during the reported follow-up period. Patients lost to follow-up were excluded from this study. All included articles clearly describe the treatment modality and the number of cured lesions. Exclusion criteria were (i) case-series with five lesions or less and (ii) studies using concomitant treatments.

Statistical analysis

The five most commonly used treatments were chosen for statistical analysis. Cure rates between the different treatment modalities were compared using a chi-square test. A significance level of 0.05 was chosen. Statistical analysis was done using SPSS advanced statistical software version 22.0 (SPSS Inc., Chicago, IL, USA).

© 2017 *The International Society of Dermatology*

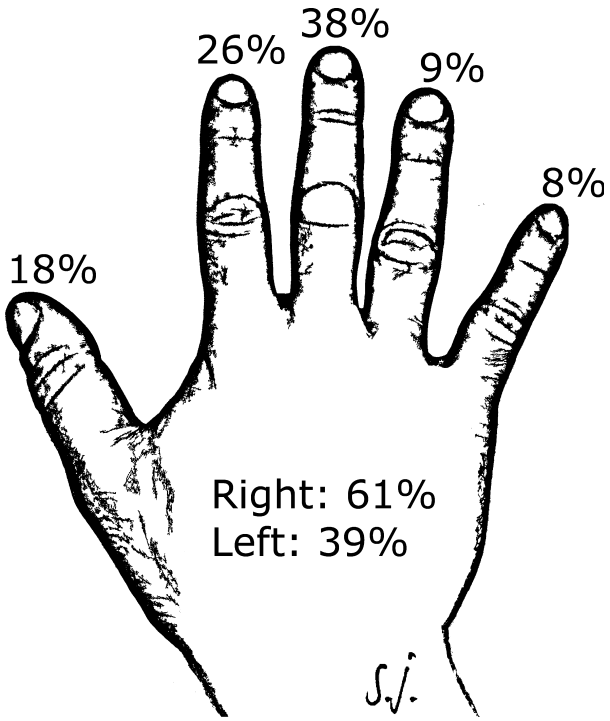

Figure 2 Distribution of mucous cysts in the hand

Table 3 Reported adverse events

Surgery	Joint stiffness
	Nail deformity
	Bleeding
	Infection
	Pain and tenderness
	Tendon injury
Sclerotherapy	Pain
	Superficial necrosis
	Joint stiffness
	Inflammation and erythema
Cryotherapy	Pain
	Discomfort
	Hemorrhagic blister
Corticosteroid injection	Infection
	Stiffness
Expression of cyst content	Inflammation
CO2 laser vaporization	Scarring
Infrared coagulation	Pain
	Erythema
	Blistering
	Scarring
	Infection

Results

The initial search and manual screening of the references yielded 370 citations. Of the 362 unique articles, 102 were retained as candidate studies based on their titles and abstracts. Following full-text review, 40 articles were included. The included studies were then compiled according to treatment modality. All the studies were published between 1969 and 2016. Twenty-six studies used surgery (Table 1), five used sclerotherapy, four used cryotherapy, two used corticosteroid injection, five used manual compression of the cyst content, two used CO2 laser vaporization, and two used infrared coagulation (Table 2). The stepwise approach for study selection is summarized in Fig. 1. Studies were further divided into nine subgroups depending on the excised component (cyst, overlying skin, and osteophyte) and the wound coverage techniques (primary closure, skin graft, or local skin flap). All studies comprise 1364 DMC lesions. The mean age of patients was 60.47 years, with a range of 13–89 and 31.79% of patients were males. Most commonly reported pre-treatment symptoms were pain, osteoarthritis, and nail deformities. Mean time of the duration of symptoms until patients sought treatment was 13 months. Ninety-four percent of lesions were located on the fingers, and 6% on the toes; 61% were on the right side and 39% on the left side. The DMC were located on the third finger in 38%, on the second in 26%, on the thumb in 18%, on the fourth finger in 9%, and on the fifth in 8% (Fig. 2). The most commonly reported adverse events for each treatment modality are reported in Table 3.

The total cure rate for all treatments, combined, was 83%. The cure rate for surgical management was 95%. Within the surgical methods, cyst and osteophyte excision with primary closure had the highest cure rate (98%) with the largest number of treated lesions (218) and was chosen as a reference for comparison with the remaining surgical techniques. Simple cyst excision, destruction of cyst pedicle and skin, and cyst and osteophyte excision with skin grafting showed a statistically significant difference when compared to the reference subgroup. The five most frequently used treatments for DMC were surgery ($n = 849$), followed by expression of cyst content ($n = 132$), sclerotherapy ($n = 119$), corticosteroid injection ($n = 108$), and cryotherapy ($n = 103$). Surgery yielded the highest cure rate among all treatment modalities (95%) with a statistically significant difference when compared to sclerotherapy (77%), cryotherapy (72%), corticosteroid injection (61%), and expression of cyst content (39%) ($P < 0.001$). Within the nonsurgical therapy subgroups, sclerotherapy had the highest cure rate (77%) and was superior to corticosteroid injection ($P = 0.008$) and expression of cyst content ($P < 0.001$) but not to cryotherapy ($P = 0.350$). Corticosteroid injection was superior to expression of cyst content ($P = 0.001$). Results are summarized in Tables 4 and 5. Key findings are outlined in Table 6.

Discussion

To date, no treatment showed a consistent success as DMC is a highly recurrent lesion. In the included studies, several surgical techniques have been described for the treatment of DMC. They consisted of cyst excision with or without concomitant debridement of underlying joint osteophytes. Overlying skin, even when

 © 2017 *The International Society of Dermatology*

Table 4 Summary of results

Procedure	Excision			Number of lesions	Number of successfully treated lesions[a]	Recurrence (Lesion *n*)[b]	Cure rate (%)	*P* value
	Skin	Cyst	Osteophyte					
Surgery studies								
Simple cyst excision		X		167	151	16	90	0.001*
Destruction of cyst pedicle				73	67	6	92	0.01*
Cyst and osteophyte excision with primary closure		X	X	218	214	4	98	
Skin and cyst excision with skin grafting	X	X		30	29	1	97	0.584
Skin and cyst excision with local flap closure	X	X		18	17	1	94	0.292
Skin, cyst, and osteophyte excision with primary closure	X	X	X	15	14	1	93	0.212
Skin, cyst, and osteophyte excision with skin grafting	X	X	X	96	90	6	94	0.04*
Skin, cyst, and osteophyte excision with local flap closure	X	X	X	170	167	3	98	0.959
Osteophyte excision			X	62	61	1	98	0.907
Surgery total				849	810	39	95	
Nonsurgical therapy studies								
Sclerotherapy[c]				119	92	27	77	<0.001*
Cryotherapy[c]				103	74	29	72	<0.001*
Corticosteroid injection				108	66	42	61	<0.001*
Expression of cyst content				132	52	80	39	<0.001*
Laser and light therapy studies								
CO2 laser vaporization				16	14	2	88	
Infrared coagulation				37	28	9	76	
Total				1364	1136	228	83	

[a]Success of treatment was defined as complete disappearance of the cyst.
[b]Recurrence is defined as reappearance of the cyst after initial complete resolution or the need for additional treatment
[c]Due to the nature of cryotherapy and sclerotherapy treatments, multiple treatment sessions were considered as normal and not a recurrence as long as it was planned in the initial treatment protocol.
*Statistically significant: The surgery subgroups were compared to cyst and osteophyte excision with primary closure subgroup, whereas nonsurgical therapies were compared to surgical therapies in total.

Table 5 *P* values for cure rates

	Surgery	Sclerotherapy	Cryotherapy	Corticosteroid injection	Expression of cyst content
Surgery		<0.001*	<0.001*	<0.001*	<0.001*
Sclerotherapy	<0.001*		0.35	0.008*	<0.001*
Cryotherapy	<0.001*	0.35			
Corticosteroid injection	<0.001*	0.008*			0.001*
Expression of cyst content	<0.001*	<0.001*		0.001*	

*Statistically significant when adjusting for comparison of surgery, sclerotherapy, cryotherapy, corticosteroid injection, and expression of cyst content at an alpha of 0.05. Comparisons are being made: surgery versus sclerotherapy, surgery versus cryotherapy, surgery versus corticosteroid injection, surgery versus expression of cyst content, sclerotherapy versus cryotherapy, sclerotherapy versus corticosteroid injection, sclerotherapy versus expression of cyst content, and corticosteroid injection versus expression of cyst content.

thinned, could heal and provide good coverage.[8,10,19,24–34] However, it was frequently excised along with the cyst. In this case, the defect was closed either by a full thickness skin graft[25,34,35] or by a local flap.[10,20,22,36–40] In our review, we demonstrated that surgery had the highest cure rate among the five most commonly used treatments: all surgical techniques had a cure rate superior to 90% with a mean of 95%. Reported drawbacks of surgery are adverse events (joint stiffness, nail deformity, bleeding, infection,

Table 6 Key points

Mean age of patients with DMC is 60.47 years, and 31.79% of patients are males
Sixty-one percent of DMC occur on the right hand and 39% on the left
In the hand, the DMC are located on the thumb in 18%, on the second finger in 26%, on the third in 38%, on the fourth in 9%, and on the fifth in 8%
The five most frequently used treatments for DMC are surgery, followed by expression of cyst content, sclerotherapy, corticosteroid injection, and cryotherapy
Surgery has the highest cure rate among all treatment modalities (95%) followed by sclerotherapy (77%), cryotherapy (72%), corticosteroid injection (61%), and expression of cyst content (39%)
Surgery targets are the cyst, the overlying skin, and the underlying osteophytes
The wound coverage techniques are: primary closure, skin graft, and local skin flap
The overlying skin, even when thinned, can heal and provide good coverage
For surgical management, attention should be made to the possible adverse events, and these must be clearly explained to the patient
Sclerotherapy and cryotherapy may require multiple treatment sessions but are less invasive than surgery and can be good alternatives for nonsurgical candidates
Corticosteroid injection and expression of cyst content are frequently used treatment modalities but have lower cure rates compared to surgery, sclerotherapy, and cryotherapy
Other less frequently used modalities include CO2 laser vaporization and infrared coagulation

DMC, digital mucous cyst.

pain and tenderness, and tendon injury), contraindications to surgery, and relatively high cost.

Five studies evaluated sclerotherapy as a treatment modality for DMC. Cure rate was 77%, which was statistically inferior to that of surgery ($P < 0.001$). The injected sclerotic agents were: polidocanol,[41,42] sodium tetradecyl sulfate,[43,44] and OK432 (lyophilized strep pyogenes).[45] In four of the five studies, treatment had to be repeated at fixed intervals to ensure cyst removal.[41–44] Cryotherapy is another noninvasive treatment method for DMC. Liquid nitrogen was applied either with a probe or by the means of an open spray technique.[46–49] The total cure rate was 72%, which was lower than the surgery cure rate ($P < 0.001$) but was not statistically different from that of sclerotherapy ($P = 0.350$).

Both sclerotherapy and cryotherapy are easy, not expensive, and noninvasive treatment modalities that offer good alternatives for nonsurgical candidates as they yield acceptable cure rates with a good safety profile.

Two studies used corticosteroid injections to treat the cysts with a total cure rate of 61%.[33,50] Simple expression of cyst content was done by needling[26,51] or needle aspiration[52,53] and had a total cure rate of 39%. CO2 laser vaporization and infrared coagulation were only used in two small case series each[12,17,18,54] with a total cure rate of 88 and 76%, respectively.

Surgery should be considered as the first-line treatment for DMC as it is the most frequently used modality with the highest cure rate. Special attention should be made to the possible

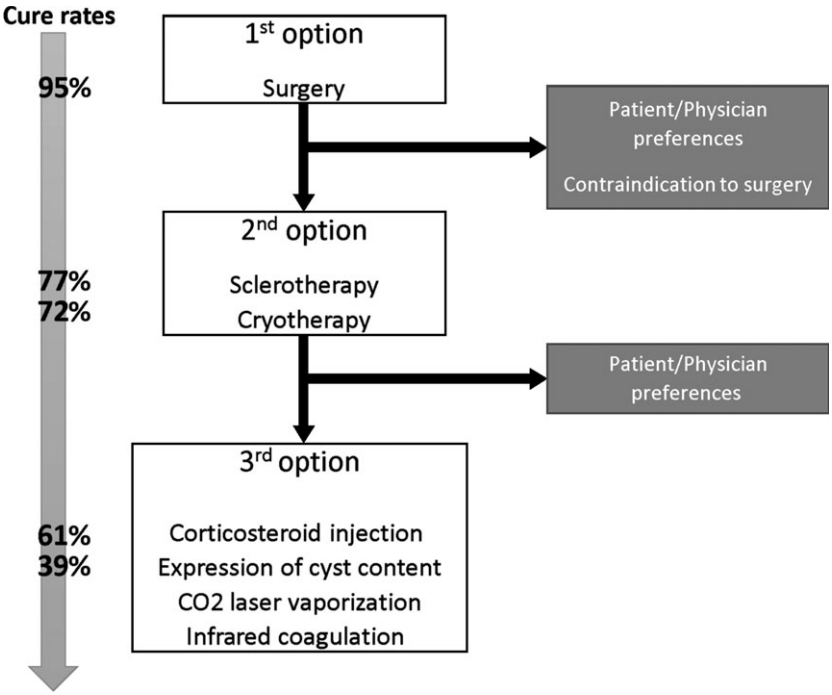

Figure 3 Proposed treatment algorithm for digital mucous cysts

 © 2017 *The International Society of Dermatology*

adverse events that must be clearly explained to the patient prior to treatment choice. Second-line treatments include sclerotherapy and cryotherapy. They may have less adverse events but can require multiple sessions. This could influence both the patient's and physician's choice of therapy. Third-line treatments include less efficient or less studied methods such as corticosteroid injection, expression of cyst content, CO2 laser vaporization, and infrared coagulation (Fig. 3).

There are several limitations to this review. Thirty-four of the included studies were retrospective and six were prospective trials. We did not find any randomized controlled trials comparing different treatment methods, which prevented us from performing a meta-analysis. Other limitations were inter-practitioner disparities and publication bias as only published articles were evaluated.

Conclusion

This review provides a practical treatment algorithm for DMC based on cure rates and guides the physician in this much-debated field. Based on available data, we found that the most commonly used treatment methods are surgery, sclerotherapy, cryotherapy, corticosteroid injection, and expression of cyst content. Among these modalities, surgery yielded the highest cure rates. Future adequately designed randomized controlled trials are warranted to compare the efficacy of these techniques.

Questions (answers provided after references)

(1) What are the most common age group and gender of patients presenting with digital myxoid cysts?
- a. Young males.
- b. Young females.
- c. Old males.
- d. Old females.

(2) Which is the most affected finger?
- a. First.
- b. Second.
- c. Third.
- d. Fourth.
- e. Fifth.

(3) What are the main reported symptoms?
- a. Pain.
- b. Nail deformities.
- c. Bleeding.
- d. Oozing.

(4) What are the most commonly used treatments for digital myxoid cysts?
- a. Surgery.
- b. Sclerotherapy.
- c. Cryotherapy.
- d. Corticosteroid injection.

(5) Which treatment modality yielded the highest cure rate?
- a. Surgery.
- b. Sclerotherapy.
- c. Cryotherapy.
- d. Corticosteroid injection.

(6) What are the potential targets of surgery?
- a. Cyst.
- b. Overlying skin.
- c. Underlying osteophytes.
- d. All of the above.

(7) A flap is mandatory after cyst removal because the overlying skin does not provide good coverage. True or False?

(8) What are the most frequently reported noninvasive treatment modalities?
- a. Sclerotherapy.
- b. Cryotherapy.
- c. Steroid injection.
- d. Laser treatment.

(9) Simple cyst drainage is an efficient treatment option. True or False?

(10) Lasers and light therapies can be used in the treatment of digital myxoid cysts. True or False?

References

1 Hernández-Lugo AM, Domínguez-Cherit J, Vega-Memije ME. Digital mucoid cyst: the ganglion type. *Int J Dermatol* 1999; **38**: 533–535.

2 De Berker DA, Lawrence CM. Treatment of myxoid cysts. *Dermatol Surg* 2001; **27**: 296–299.

3 Mani-Sundaram D. Surgical correction of mucous cysts of the nail unit. *Dermatol Surg* 2001; **27**: 267–268.

4 Kivanc-Altunay I, Kumbasar E, Gokdemir G, *et al.* Unusual localization of multiple myxoid (mucous) cysts of toes. *Dermatol Online J* 2004; **10**: 23.

5 de Berker D, Goettman S, Baran R. Subungual myxoid cysts: clinical manifestations and response to therapy. *J Am Acad Dermatol* 2002; **46**: 394–398.

6 Johnson WC, Graham JH, Helwig EB. Cutaneous myxoid cyst. A clinicopathological and histochemical study. *JAMA* 1965; **191**: 15–20.

7 Fritz GR, Stern PJ, Dickey M. Complications following mucous cyst excision. *J Hand Surg Edinb Scotl* 1997; **22**: 222–225.

8 Lawrence C. Skin excision and osteophyte removal is not required in the surgical treatment of digital myxoid cysts. *Arch Dermatol* 2005; **141**: 1560–1564.

9 Sonnex TS. Digital myxoid cysts: a review. *Cutis* 1986; **37**: 89–94.

10 Crawford RJ, Gupta A, Risitano G, *et al.* Mucous cyst of the distal interphalangeal joint: treatment by simple excision or excision and rotation flap. *J Hand Surg Edinb Scotl* 1990; **15**: 113–114.

11 Kleinert HE, Kutz JE, Fishman JH, *et al.* Etiology and treatment of the so-called mucous cyst of the finger. *J Bone Joint Surg Am* 1972; **54**: 1455–1458.

12 Lonsdale-Eccles AA, Langtry JA. Treatment of digital myxoid cysts with infrared coagulation: a retrospective case series. *Br J Dermatol* 2005; **153**: 972–975.

© 2017 *The International Society of Dermatology*

13 Butler DF, Davis G, Greene JF. Multiple mucinous (myxoid) cysts of a single finger. *J Am Acad Dermatol* 2005; **53**: 914–916.
14 Truhan AP, Roenigk HH. The cutaneous mucinoses. *J Am Acad Dermatol* 1986; **14**: 1–18.
15 Zuber TJ. Office management of digital mucous cysts. *Am Fam Physician* 2001; **64**: 1987–1990.
16 Sonnex TS, Dawber RP. Cryosurgery for digital mucoid cysts. *J Dermatol Surg Oncol* 1983; **9**: 714.
17 Huerter CJ, Wheeland RG, Bailin PL, *et al.* Treatment of digital myxoid cysts with carbon dioxide laser vaporization. *J Dermatol Surg Oncol* 1987; **13**: 723–727.
18 Kemmett D, Colver GB. Myxoid cysts treated by infra-red coagulation. *Clin Exp Dermatol* 1994; **19**: 118–120.
19 de Berker D, Lawrence C. Ganglion of the distal interphalangeal joint (myxoid cyst): therapy by identification and repair of the leak of joint fluid. *Arch Dermatol* 2001; **137**: 607–610.
20 Young KA, Campbell AC. The bilobed flap in treatment of mucous cysts of the distal interphalangeal joint. *J Hand Surg Edinb Scotl* 1999; **24**: 238–240.
21 Eaton RG, Dobranski AI, Littler JW. Marginal osteophyte excision in treatment of mucous cysts. *J Bone Joint Surg Am* 1973; **55**: 570–574.
22 Imran D, Koukkou C, Bainbridge LC. The rhomboid flap: a simple technique to cover the skin defect produced by excision of a mucous cyst of a digit. *J Bone Joint Surg Br* 2003; **85**: 860–862.
23 Shin EK, Jupiter JB. Flap advancement coverage after excision of large mucous cysts. *Tech Hand Up Extrem Surg* 2007; **11**: 159–162.
24 Kasdan ML, Stallings SP, Leis VM, *et al.* Outcome of surgically treated mucous cysts of the hand. *J Hand Surg* 1994; **19**: 504–507.
25 Constant E, Royer JR, Pollard RJ, *et al.* Mucous cysts of the fingers. *Plast Reconstr Surg* 1969; **43**: 241–246.
26 Abe Y, Watson HK, Renaud S. Flexor tendon sheath ganglion: analysis of 128 cases. *Hand Surg Int J* 2004; **9**: 1–4.
27 Arenas-Prat J. Digital mucous cyst excision using a proximally based skin flap. *J Plast Surg Hand Surg* 2015; **49**: 189–190.
28 Kanaya K, Wada T, Iba K, *et al.* Total dorsal capsulectomy for the treatment of mucous cysts. *J Hand Surg* 2014; **39**: 1063–1067.
29 Brown RE, Zook EG, Russell RC, *et al.* Fingernail deformities secondary to ganglions of the distal interphalangeal joint (mucous cysts). *Plast Reconstr Surg* 1991; **87**: 718–725.
30 Hoshino Y, Saito N, Kuroda H. Surgical treatment of mucous cysts on fingers without skin excision. *Hand Surg Int J* 2010; **15**: 145–148.
31 Gingrass MK, Brown RE, Zook EG. Treatment of fingernail deformities secondary to ganglions of the distal interphalangeal joint. *J Hand Surg* 1995; **20**: 502–505.
32 Lee H-J, Kim P-T, Jeon I-H, *et al.* Osteophyte excision without cyst excision for a mucous cyst of the finger. *J Hand Surg Eur* 2014; **39**: 258–261.
33 Rizzo M, Beckenbaugh RD. Treatment of mucous cysts of the fingers: review of 134 cases with minimum 2-year follow-up evaluation. *J Hand Surg* 2003; **28**: 519–524.
34 Baazil H, Dalemans A, De Smet L, *et al.* Comparison of surgical treatments for mucous cysts of the distal interphalangeal joint. *Acta Orthop Belg* 2015; **81**: 213–217.
35 Jamnadas-Khoda B, Agarwal R, Harper R, *et al.* Use of Wolfe graft for the treatment of mucous cysts. *J Hand Surg Eur* 2009; **34**: 519–521.
36 Hojo J, Omokawa S, Shigematsu K, *et al.* Patient-based outcomes following surgical debridement and flap coverage of digital mucous cysts. *J Plast Surg Hand Surg* 2016; **50**: 111–114.
37 Jager T, Vogels J, Dautel G. The Zitelli design for bilobed flap applied on skin defects after digital mucous cyst excision. A review of 9 cases. *Tech Hand Up Extrem Surg* 2012; **16**: 124–126.
38 Johnson SM, Treon K, Thomas S, *et al.* A reliable surgical treatment for digital mucous cysts. *J Hand Surg Eur* 2014; **39**: 856–860.
39 MacCollum MS. Mucous cysts of the fingers. *Br J Plast Surg* 1975; **28**: 118–120.
40 Blanc S, Candelier G, Bonnan J, Faure P. [Use of a bilobed flap for the treatment of mucous cysts]. *Chir Main* 2004; **23**: 137–141.
41 Córdoba S, Romero A, Hernández-Nuñez A, *et al.* Treatment of digital mucous cysts with percutaneous sclerotherapy using polidocanol. *Dermatol Surg* 2008; **34**: 1387–1388; discussion 1388.
42 Esson GA, Holme SA. Treatment of 63 subjects with digital mucous cysts with percutaneous sclerotherapy using polidocanol. *Dermatol Surg* 2016; **42**: 59–62.
43 Park SE, Park EJ, Kim SS, *et al.* Treatment of digital mucous cysts with intralesional sodium tetradecyl sulfate injection. *Dermatol Surg* 2014; **40**: 1249–1254.
44 Sung JY, Roh MR. Efficacy and safety of sclerotherapy for digital mucous cysts. *J Dermatol Treat* 2014; **25**: 415–418.
45 Tanaka Y, Takakura Y, Kumai T, *et al.* Sclerotherapy for intractable ganglion cyst of the hallux. *Foot Ankle Int* 2009; **30**: 128–132.
46 Böhler-Sommeregger K, Kutschera-Hienert G. Cryosurgical management of myxoid cysts. *J Dermatol Surg Oncol* 1988; **14**: 1405–1408.
47 Dawber RP, Sonnex T, Leonard J, *et al.* Myxoid cysts of the finger: treatment by liquid nitrogen spray cryosurgery. *Clin Exp Dermatol* 1983; **8**: 153–157.
48 Kuflik EG. Specific indications for cryosurgery of the nail unit. Myxoid cysts and periungual verrucae. *J Dermatol Surg Oncol* 1992; **18**: 702–706.
49 Minami S, Nakagawa N, Ito T, *et al.* A simple and effective technique for the cryotherapy of digital mucous cysts. *Dermatol Surg* 2007; **33**: 1280–1282.
50 Dodge LD, Brown RL, Niebauer JJ, *et al.* The treatment of mucous cysts: long-term follow-up in sixty-two cases. *J Hand Surg* 1984; **9**: 901–904.
51 Epstein E. A simple technique for managing digital mucous cysts. *Arch Dermatol* 1979; **115**: 1315–1316.
52 Esteban JM, Oertel YC, Mendoza M, *et al.* Fine needle aspiration in the treatment of ganglion cysts. *South Med J* 1986; **79**: 691–693.
53 Rollins KE, Ollivere BJ, Johnston P. Predicting successful outcomes of wrist and finger Ganglia. *Hand Surg Int J* 2013; **18**: 41–44.
54 Karrer S, Hohenleutner U, Szeimies RM, *et al.* Treatment of digital mucous cysts with a carbon dioxide laser. *Acta Derm Venereol* 1999; **79**: 224–225.
55 Calder JDF, Buch B, Hennessy MS, *et al.* Treatment of mucous cysts of the toes. *Foot Ankle Int* 2003; **24**: 490–493.

Answers

(1) c; (2) c; (3) a and b; (4) a; (5) a; (6) d; (7) False; (8) a and b; (9) False; (10) True.

 © 2017 *The International Society of Dermatology*